

clinical decision making and the lack of easy-to-use electronic risk calculators [34].

Pathophysiology

The pathophysiology of CI-AKI is multifactorial and it is based on a combination of mechanisms, including direct cytotoxic effects, auto-, para- and endocrine factors. Of note, these factors act on pre-existing individual risk profile and hydration status (Figure 2).

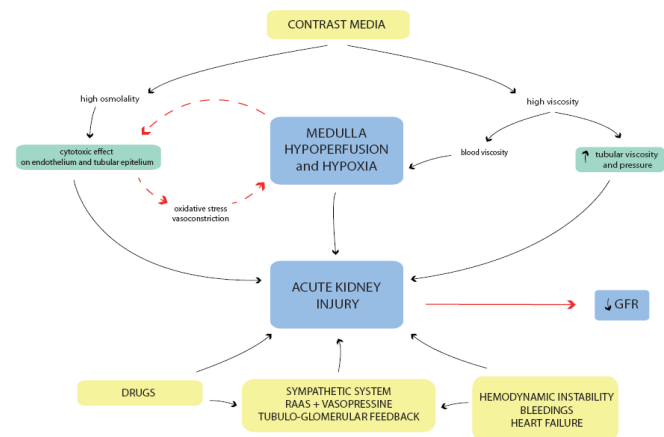


Figure 2: Contrast induced-acute kidney injury (CI-AKI) pathophysiology based on a combination of mechanisms including direct cytotoxic effect, auto, para and endocrine factors. Renal medullary hypoxia plays a central role in the pathophysiology of CI-AKI [15-17,39,40]. In particular, medullary hypoperfusion magnifies contrast media (CM) cytotoxicity initiating a vicious circle between direct CM toxic effect and renal damage (GFR: Glomerular Filtration Rate).

Iodinated CM exert cytotoxic effect *in vitro* and *in vivo* on epithelial tubular cells [35,36]. The extent of this direct cytotoxic damage is related to the duration of the exposure of these cells to the CM [22]. It was shown that CM can reduce cell proliferation and reversibly alter mitochondrial function in a porcine tubule cell line [37]. This effect was linked to CM ionicity, molecular structure and osmolality. In particular, low-osmolar (LO) CM affect mitochondrial function to a lesser extent compared to iso-osmolar (IO) and high-osmolar (HO)CM [37]. Moreover, HOCM are associated with an increased concentration of adenosine as compared with LOCM. Adenosine is connected to the generation of reactive oxygen species (ROS) promoting oxidative stress and renal vasoconstriction [38,39]. CM in the renal medulla can affect the fragile balance between vasodilatory and vasoconstrictive factors and result in medullary hypoperfusion, mainly caused by constricting descending vasa recta (DVR) [40]. CM exert a vasoconstrictor effect also in the renal cortex, inducing pre-glomerular vasoconstriction and a consequent reduction in GFR [36]. High osmolality amplifies the intrinsic cytotoxicity and the hypoxic effect of

CM, compared to lower osmolality. As a result, HOCM are associated with high nephrotoxicity [35,41].

On the other hand, the introduction of IOCM was associated with an increase in viscosity as compared to HOCM. High viscosity significantly slows tubular flow, increases tubular pressure and intrarenal retention time of CM [42].

Furthermore, high viscosity is associated with elevated interstitial and vascular pressures [42], accordingly reducing medullary blood flow and favoring hypoperfusion.

Through the alteration of renal tubulo- and haemo-dynamic, high viscosity of CM may eventually play an important role in the pathophysiology of the CI-AKI.

CM exert their damaging effects mostly by inducing renal hypoperfusion [35,43], holding renal medullary hypoxia a key position in the pathophysiology of CI-AKI.

Of note, renal hypoxic insult is worsened by the activation of sympathetic system and the hormonal response [44]. In AKI, the activation of the sympathetic system, the increased renin-angiotensin-aldosterone activity and the activation of tubular-glomerular feedback lead to a relevant renal vasoconstriction. Simultaneously, arginine vasopressin is released and contributes to water retention [44]. Additionally, drugs seem to contribute to AKI in about 20% of patients, especially in critically ill patients [45]. Frequently prescribed drugs such as non-steroidal anti-inflammatory drugs, antibiotics like β -lactam antibiotics, aminoglycosides or sulphonamides, angiotensin-converting-enzyme inhibitors and angiotensin-receptor blockers may contribute to AKI.

Clinical implications

CI-AKI has been associated with adverse short- and long-term outcomes including mortality and cardiovascular events, worsening of renal function and prolongation of hospital stay [1,26,46].

The association of CI-AKI with mortality varies significantly among studies published over the years. Results are influenced by study design and data analysis so that patient selection criteria, CI-AKI definition and adjustment for confounders may affect the values.

The association of CI-AKI and mortality in patients undergoing PCI is deeply influenced by the clinical, elective or emergent, setting. CI-AKI was found to be less frequent and less associated with mortality and other adverse outcomes in stable patients when compared to acute coronary syndrome (ACS) [7,26]. In particular, among patients with ACS, those presenting with STEMI have been shown to exhibit a more complicated course compared to NSTEMI patients [47].

Crimi et al. found that the adjusted prognostic impact of CI-AKI on the composite endpoint (death, stroke, myocardial infarction) was worse in patients with stable coronary artery disease than in patients with ACS (p for multivariable-adjusted interaction=0.048) [26] (Figure 3).

Multivariable-adjusted interactions

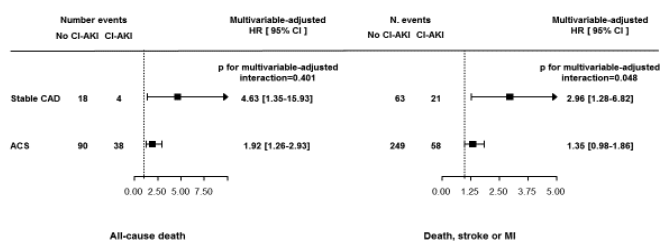


Figure 3: The impact of contrast induced acute kidney injury (CI-AKI) on the composite endpoint (death, stroke, myocardial infarction) is worse in patients with stable coronary artery disease (CAD) than in patients with acute coronary syndromes (ACS).

A meta-analysis published in 2013 confirmed the association between CI-AKI and an increased risk of mortality (pooled adjusted risk ratio 2.39; 95% CI 1.98-2.90; I²=88.3%) and of cardiovascular events (pooled adjusted risk ratio 1.98 95% CI 1.52-2.59) in patients undergoing coronary angiography [1]. However, the association between CI-AKI and mortality was strongly confounded by baseline clinical characteristics that simultaneously predispose to both kidney injury and mortality [1].

Of note, CKD is an independent predictor for the development of CI-AKI, but it is also associated with higher mortality [2,3]. In particular, the progression to CKD strongly affects prognosis and mortality. For example, its frequency post-PCI varies from <1% in the general population 48 to 7% in patients with CKD [49].

A recently published study including patients with ACS undergoing PCI reported higher rate of CI-AKI post-PCI and also higher 5 year mortality rates in patients with persistently impaired renal function (defined as a >0.5 mg/dl or >25% increase of SCr levels 6-8 months after PCI) compared to the group who had no persistent of renal function (25% vs. 9.4%, p=0.0006) [46]. CI-AKI was an independent predictor for the development of persistent impairment of renal function (40% in patients with CI-AKI vs. 11% in the control group) [46].

Prevention and management

The increasing use of CM in clinical practice and the consequent increasing risk of CI-AKI, with its relevant clinical implications, put the need preventive measures and potential treatment of CI-AKI.

First of all, following “primum non nocere”, it should be used the minimum amount of contrast needed, avoiding HOCM for their high nephrotoxicity [50]. All non essential-nephrotoxic medications should to be stopped for 24 hours prior and for 48 hours following the procedure [50]. Interestingly, data from a recently published trial, combined with reports from CKD trials, suggest that intensive renin-angiotensin system (RAS) inhibition appears to have deleterious effects in the setting of hospitalization and

probably in the setting of cardiac catheterization and PCI [51,52]. The Angiotensin Converting Enzyme Inhibitor/Angiotensin Receptor Blocker and Contrast Induced Nephropathy in Patients Receiving Cardiac Catheterization (CAPTAIN) trial randomized 208 patients with CKD to continue or hold RAS inhibitor 24 h before coronary angiography [53]. At 48-96 hours, CI-AKI occurred in 10.9% of RAS inhibitor-held compared to 18.4% of RAS inhibitors-continued patients (hazard ratio [HR]: 0.59; 95% CI 0.30-1.19; p=0.16). Of note, the composite endpoint of death, MI, ischemic stroke, congestive heart failure, rehospitalization for cardiovascular cause or need for dialysis periprocedural occurred majorly in patients who continued RAS inhibitors (3.9% vs. 0% in the RAS inhibitor-held group, HR: 0.11; 95% CI 0.01-2.96; p=0.06) [53]. RAS inhibitors have a chronic beneficial effect on kidney by reducing intraglomerular pressure. However, in the setting of acute illness or after administration of iodinated CM, this mechanism may be harmful, due to the inhibition of tubule-glomerular feedback and of the ability in maintaining glomerular filtration and forward flow of urine through the proximal tubules.

Pharmacological and non-pharmacological preventive strategies have been proposed (Figure 4). Among pharmacological strategies, even if small randomized trials and meta-analyses showed benefit with specific agents such as N-acetylcysteine, ascorbic acid, aminophylline, trimetazidine or fenoldopam, in large randomized clinical trials every agent tested to date has failed to prevent or treat CI-AKI [54,56].

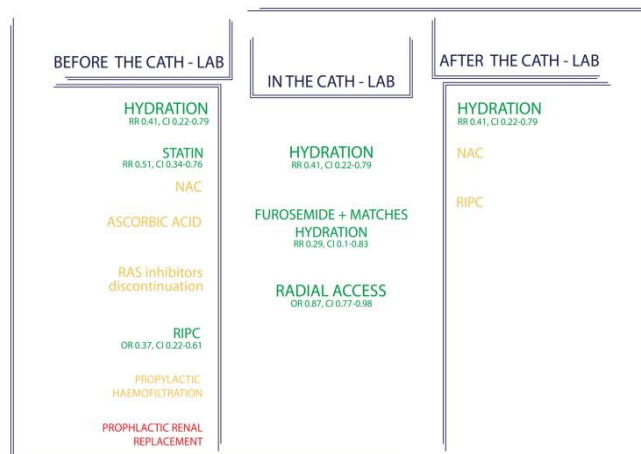


Figure 4: Contrast induced-acute kidney injury (CI-AKI) treatments that may be performed before the catheterization laboratory, in the catheterization laboratory and after the catheterization laboratory. The green therapies showed to be effective in reducing CI-AKI; the yellow one effect is still controversial; the red treatments are not effective (NAC: N-Acetylcysteine; RAS: Renine-Angiotensin System; RIPC: Remote Ischemic Conditioning).

The most widely studied pharmacological strategy for prophylaxis of CI-AKI is N-acetylcysteine (NAC). NAC has direct vasodilating effects on kidney vessels, contributing to improved renal hemodynamics [57]. It also attenuates endothelial dysfunction and it has anti-oxidant power. However, its efficacy in prevention of CI-AKI is still

debated, being the results of different meta-analysis controversial [58,59].

High-dose statins before catheterization have been demonstrated to reduce the incidence of CI-AKI [55]. Statins may be nephro-protective via several mechanisms, including inhibition of uptake of contrast into renal tubular cells, attenuation of endothelial dysfunction and oxidative stress, antiinflammation, antiproliferation of mesangial cells, and protection of podocytes. The Protective effect of Rosuvastatin and Antiplatelet Therapy On contrast-induced acute kidney injury and myocardial damage in patients with Acute Coronary Syndrome (PRATO-ACS) trial demonstrated that statin group had a significantly lower rate of CI-AKI as compared to the no-statin group (6.7% vs. 15.1%; adjusted odds ratio [OR]: 0.38; 95% CI 0.20-0.71; $p=0.003$) [60]. Moreover, there was a decrease in 30-day composite death, dialysis, MI, stroke, or persistent renal damage in the statin group (3.6% vs. 7.9%, respectively; $p=0.036$), and a trend toward a decrease in death or MI at 6 months (3.6% vs. 7.2%, respectively; $p=0.07$) [60]. In patients with diabetes and CKD who were undergoing coronary or peripheral angiography, with or without intervention, rosuvastatin was effective in reducing the incidence of CI-AKI (2.3% vs. 3.9%; $p=0.01$) [61].

Hydration plays a pivotal role in prevention of CI-AKI, being the most effective measure to prevent and treat CI-AKI. It preserves renal perfusion and suppresses renine-angiotensin-aldosterone system, the tubule-glomerular feedback and vasopressin, supporting high urine flow rates and lowering CM concentration in tubular fluids. In ambulant stable patients, oral route may be as effective as the intravenous one; conversely in hospitalized patients intravenous hydration has been demonstrated superior in clinical trials [62]. Solomon and colleagues were the first to show in a randomized trial that 45% saline administration at a rate of 1 mL/kg per hour for 12 hours before and after the procedure was more effective than a combination of 0.45% saline with mannitol or furosemide (10.7% vs. 28.0% vs. 40.0%, respectively; $P=0.02$ for comparison with the saline group alone) [63].

Numerous randomized trials compared isotonic bicarbonate solutions to intravenous saline, finding no differences in the rates of renal outcomes [64,65]. Either isotonic crystalloid solution is recommended, with some guidance on the quantity of fluid according to patient factors. The current European guidelines recommend hydration with sodium chloride 0.9% at 1-1.5 ml/kg/h for 12 hours before the procedure and up to 24 hours after the procedure [50]. These recommendations are too general and often do not fit with the heterogeneity of patients presenting during clinical practice. Interestingly, Brar et al. proposed a patient-specific approach for patients undergoing cardiac catheterization: The Prevention of Contrast Renal Injury with Different Hydration Strategies (POSEIDON) trial showed that a strategy of measurement of left ventricular end-diastolic pressure (LVEDP) and expanding plasma volume was associated with more intensive fluid administration during and after the procedure and with a reduction in CI-AKI compared with the

control group (6.7% vs. 16.3% relative risk [RR] 0.41, 95% CI 0.22-0.79; $p=0.005$) [66].

Use of loop diuretics is associated to higher rate of CI-AKI in patients with CKD undergoing PCI [67]. However, it has been shown that volume contraction imposed by furosemide is effective in preventing CI-AKI when counterbalanced by volume supplementation [68,69]. In fact, the Renalguard device adjusts the rate of intravenous saline infusion to match the urine output, providing either volume expansion and valid diuresis. Elevation of urine output to >150 ml/h before and during the procedure significantly reduced the incidence of CI-AKI in patients with chronic kidney disease [69] and in high-risk patients [68,70]. In particular, a recently published study suggested that an intraprocedural urine flow rate of ≥ 450 ml/h is the best threshold for an optimal CI-AKI prevention [71].

In the pathophysiology of CI-AKI medullary vasoconstriction may cause ischemic/reperfusion injury. Remote ischemic conditioning (RIC), including remote ischemic pre-conditioning and remote ischemic post-conditioning, has shown to reduce ischemic/reperfusion injury in several organs and clinical settings [72]. A recent meta-analysis showed that remote ischemic conditioning reduced the incidence of CI-AKI compared to the control group (OR 0.52, 95% CI 0.34-0.77, $p=0.001$) [73]. Thus, despite the mechanisms underlying RIC are not completely cleared, it represents an intriguing intervention for reducing ischemic/reperfusion injury and improving clinical outcomes.

Importantly, it has been recently shown that radial access may be beneficial in reducing the risk of CI-AKI in patients with acute coronary syndromes undergoing PCI as compared with femoral access [74]. AKI was reduced in the radial access group (15.4% in the radial access group vs. 17.4% in the femoral access group; OR 0.87, 95% CI 0.77-0.98; $p=0.018$) [74]. Despite these results require future confirmation, they are of clinical relevance and mainly linked to the reduction in access related bleeding events; thus trans-radial approach to perform invasive procedures should be counted among the preventing measures that reduce the risk of CI-AKI.

Conclusion

CI-AKI remains a concern for patients undergoing diagnostic and therapeutic procedures which require iodinated contrast administration. A general consensus is warranted for a correct definition and, consequently, a more precise definition of incidence and prognostic implication of CI-AKI. Better biomarkers are also required to achieve the diagnosis earlier and more accurately.

To date, the best strategy to prevent CI-AKI is to expand intravascular volume, to support high urine flow rates and to limit CM concentration in tubular fluids. Although no adjunctive therapy has been conclusively demonstrated to reduce CI-AKI incidence, preventive administration of statins and discontinuation of RAS inhibitors ≥ 24 hours before contrast exposure, showed to be effective in renal protection.

Further research is needed in the development of new prophylactic and therapeutic strategies.

References

1. James MT, Samuel SM, Manning MA, et al. (2013) Contrast-induced acute kidney injury and risk of adverse clinical outcomes after coronary angiography: A systematic review and meta-analysis. *Circ Cardiovasc Interv* 6(1): 37-43.
2. Kini AS, Sarkar K, Rafael OC, et al. (2009) Serum creatinine ratio: A novel predictor of mortality after percutaneous coronary intervention in patients with normal and abnormal renal function. *Catheter Cardiovasc Interv* 74(1): 49-55.
3. Dangas G, Iakovou I, Nikolsky E, et al. (2005) Contrast-induced nephropathy after percutaneous coronary interventions in relation to chronic kidney disease and hemodynamic variables. *Am J Cardiol* 95(1): 13-19.
4. Tsai TT, Patel UD, Chang TI, et al. (2014) Contemporary incidence, predictors, and outcomes of acute kidney injury in patients undergoing percutaneous coronary interventions: insights from the NCDR Cath-PCI Registry. *J Am Coll Cardiol Intv* 7(1): 1-9.
5. McCullough PA, Adam A, Becker CR, et al. (2006) Epidemiology and prognostic implications of contrast-induced nephropathy. *Am J Cardiol* 98(6A): 5k-13k.
6. McCullough PA, Wolyn R, Rocher LL, et al. (1997) Acute renal failure after coronary intervention: Incidence, risk factors, and relationship to mortality. *Am J Med* 103(5): 368-375.
7. Stacul F, van der Molen AJ, Reimer P, et al. (2011) Contrast induced nephropathy: Updated ESUR contrast media safety committee guidelines. *Eur Radiol* 21(12): 2527-2541.
8. Ohno Y, Maekawa Y, Miyata H, et al. (2013) Impact of periprocedural bleeding on incidence of contrast induced acute kidney injury in patients treated with percutaneous coronary intervention. *J Am Coll Cardiol* 62(14): 1260-1266.
9. Chong E, Poh KK, Liang S, et al. (2010) Comparison of risks and clinical predictors of contrast-induced nephropathy in patients undergoing emergency versus nonemergency percutaneous coronary interventions. *J Interv Cardiol* 23(5): 451-459.
10. Owen RJ, Hiremath S, Myers A, et al. (2014) Canadian association of radiologists consensus guidelines for the prevention of contrast-induced nephropathy: Update 2012. *Can Assoc Radiol J* 65(2): 96-105.
11. Seeliger E, Sendeski M, Rihal CS, et al. (2012) Contrast-induced kidney injury: mechanisms, risk factors, and prevention. *Eur Heart J* 33(16): 2007-2015.
12. Solomon R, Dauerman HL (2010) Contrast-induced acute kidney injury. *Circulation* 122(23): 2451-2455.
13. Thomsen HS (2003) Guidelines for contrast media from the European Society of Urogenital Radiology. *AJR Am J Roentgenol* 181(6): 1463-1471.
14. Fliser D, Laville M, Covic A, et al. (2012) A European Renal Best Practice (ERBP) position statement on the Kidney Disease Improving Global Outcomes (KDIGO) clinical practice guidelines on acute kidney injury: Part 1: Definitions, conservative management and contrast-induced nephropathy. *Nephrol Dial Transplant* 27(12): 4263-4272.
15. Solomon R, Deray G (2006) How to prevent contrast-induced nephropathy and manage risk patients: Practical recommendations. *Kidney Int Suppl* 100: S51-S53.
16. Slocum NK, Grossman PM, Moscucci M, et al. (2012) The changing definition of contrast-induced nephropathy and its clinical implications: Insights from the Blue Cross Blue Shield of Michigan Cardiovascular Consortium (BMC2). *Am Heart J* 163(5): 829-834.
17. Marenzi G, Lauri G, Assanelli E, et al. (2004) Contrast-induced nephropathy in patients undergoing primary angioplasty for acute myocardial infarction. *J Am Coll Cardiol* 44(9): 1780-1785.
18. Mehran R, Aymong ED, Nikolsky E, et al. (2004) A simple risk score for prediction of contrast-induced nephropathy after percutaneous coronary intervention: Development and initial validation. *J Am Coll Cardiol* 44(7): 1393-1399.
19. Budano C, Levis M, D'Amico M, et al. (2011) Impact of contrast-induced acute kidney injury definition on clinical outcomes. *Am Heart J* 161(5): 963-971.
20. Marenzi G, Cosentino N, Moltrasio M, et al. (2016) Acute kidney injury definition and in-hospital mortality in patients undergoing primary percutaneous coronary intervention for ST-segment elevation myocardial infarction. *J Am Heart Assoc* 5(7).
21. McCullough PA (2008) Radiocontrast-induced acute kidney injury. *Nephron Physiol* 109: 61-72.
22. McCullough PA (2008) Contrast-induced acute kidney injury. *J Am Coll Cardiol* 51(15): 1419-1428.
23. Moran SM, Myers BD (1985) Course of acute renal failure studied by a model of creatinine kinetics. *Kidney Int* 27(6): 928-937.
24. Waikar SS, Bonventre JV (2009) Creatinine kinetics and the definition of acute kidney injury. *J Am Soc Nephrol* 20(3): 672-679.
25. Lin J, Fernandez H, Shashaty MG, et al. (2015) False-positive rate of aki using consensus creatinine- based criteria. *Clin J Am Soc Nephrol* 10(10): 1723-1731.
26. Crimi G, Leonardi S, Costa F, et al. (2015) Incidence, prognostic impact, and optimal definition of contrast-induced acute kidney injury in consecutive patients with stable or unstable coronary artery disease undergoing percutaneous coronary intervention insights from the all-comer PRODIGY trial. *Catheter Cardiovasc Interv* 86(1): 19-27.
27. Haase M, Bellomo R, Devarajan P, et al. (2009) Accuracy of neutrophil gelatinase-associated lipocalin (NGAL) in diagnosis and prognosis in acute kidney injury: A systematic review and meta-analysis. *Am J Kidney Dis* 54(6): 1012-1024.
28. Maisel AS, Wetterson N, van Veldhuisen DJ, et al. (2016) Neutrophil gelatinase-associated lipocalin for acute kidney injury during acute heart failure hospitalizations: The AKINESIS study. *J Am Coll Cardiol* 68(13): 1420-1431.
29. Shlipak MG, Matsushita K, Arnlov J, et al. (2013) Cystatin C versus creatinine in determining risk based on kidney function. *N Engl J Med* 369: 932-943.
30. Liu Y, Guo W, Zhang J, et al. (2013) Urinary interleukin 18 for detection of acute kidney injury: A meta-analysis. *Am J Kidney Dis* 62(6): 1058-1067.
31. Bartholomew BA, Harjai KJ, Dukkipati S, et al. (2004) Impact of nephropathy after percutaneous coronary intervention and a method for risk stratification. *Am J Cardiol* 93(12): 1515-1519.
32. Tziakas D, Chalikias G, Stakos D, et al. (2013) Development of an easily applicable risk score model for contrast-induced nephropathy prediction after percutaneous coronary intervention: A novel approach tailored to current practice. *Int J Cardiol* 163(1): 46-55.
33. Buratti S, Marenzi M, Cornara S, et al. (2016) Pre-procedural risk score for contrast induced- acute kidney injury development in ST elevation myocardial infarction in patients undergoing primary percutaneous coronary intervention. ESC congress.
34. Silver SA, Shah PM, Chertow GM, et al. (2015) Risk prediction models for contrast induced nephropathy: Systematic review. *BMJ* 351: 4395.
35. Sendeski MM (2011) The pathophysiology of renal tissue damage by iodinated contrast media. *Clin Exp Pharmacol Physiol* 38(5): 292-299.

36. Thomsen HS, Morcos SK, Barrett BJ (2008) Contrast-induced nephropathy: the wheel has turned 360 degrees. *Acta Radiol* 49(6): 646-657.
37. Hardiek K, Katholi RE, Ramkumar V, et al. (2001) Proximal tubule cell response to radiographic contrast media. *Am J Physiol Renal Physiol* 280(1): F61-F70.
38. Katholi RE, Taylor GJ, McCann WP, et al. (1995) Nephrotoxicity from contrast media: Attenuation with theophylline. *Radiology* 195(1): 17-22.
39. Schnackenberg CG (2002) Physiological and pathophysiological roles of oxygen radicals in the renal microvasculature. *Am J Physiol Regul Integr Comp Physiol* 282(2): R335-R342.
40. Sendeski M, Patzak A, Pallone TL, et al. (2009) Iodixanol, constriction of medullary descending vasa recta, and risk for contrast medium-induced nephropathy. *Radiology* 251: 697-704.
41. Pannu N, Wiebe N, Tonelli M (2006) Prophylaxis strategies for contrast-induced nephropathy. *JAMA* 295(23): 2765-2779.
42. Seeliger E, Flemming B, Wronski T, et al. (2007) Viscosity of contrast media perturbs renal hemodynamics. *J Am Soc Nephrol* 18(11): 2912-2920.
43. Bartorelli AL, Marenzi G (2008) Contrast-induced nephropathy. *J Interv Cardiol* 21(1): 74-85.
44. Schrier RW, Wang W (2004) Acute renal failure and sepsis. *N Engl J Med* 351: 159-169.
45. Bentley ML, Corwin HL, Dasta J (2010) Drug-induced acute kidney injury in the critically ill adult: Recognition and prevention strategies. *Crit Care Med* 38(6): S169-S174.
46. Nemoto N, Iwasaki M, Nakanishi M, et al. (2014) Impact of continuous deterioration of kidney function 6 to 8 months after percutaneous coronary intervention for acute coronary syndrome. *Am J Cardiol* 113(10): 1647-1651.
47. Wickenbrock I, Perings C, Maagh P, et al. (2009) Contrast medium induced nephropathy in patients undergoing percutaneous coronary intervention for acute coronary syndrome: Differences in STEMI and NSTEMI. *Clin Res Cardiol* 98(12): 765-772.
48. Freeman RV, O'Donnell M, Share D, et al. (2002) Nephropathy requiring dialysis after percutaneous coronary intervention and the critical role of an adjusted contrast dose. *Am J Cardiol* 90(10): 1068-1073.
49. Gruberg L, Mintz GS, Mehran R, et al. (2000) The prognostic implications of further renal function deterioration within 48 h of interventional coronary procedures in patients with pre-existent chronic renal insufficiency. *J Am Coll Cardiol* 36: 1542-1548.
50. Windecker S, Kolh P, Alfonso F, et al. (2014) 2014 ESC/EACTS Guidelines on myocardial revascularization: The task force on myocardial revascularization of the European Society of Cardiology (ESC) and the European Association for Cardio-Thoracic Surgery (EACTS) developed with the special contribution of the European Association of Percutaneous Cardiovascular Interventions (EAPCI). *Eur Heart J* 35(37): 2541-2619.
51. Fried LF, Duckworth W, Zhang JH, et al. (2009) Design of combination angiotensin receptor blocker and angiotensin converting enzyme inhibitor for treatment of diabetic nephropathy (VA NEPHRON-D). *Clin J Am Soc Nephrol* 4(2): 361-368.
52. Parving HH, Brenner BM, McMurray JJ, et al. (2012) Cardiorenal end points in a trial of aliskiren for type 2 diabetes. *N Engl J Med* 367: 2204-2213.
53. Bainey KR, Rahim S, Etherington K, et al. (2015) Effects of withdrawing vs continuing renin-angiotensin blockers on incidence of acute kidney injury in patients with renal insufficiency undergoing cardiac catheterization: Results from the angiotensin converting enzyme inhibitor/angiotensin receptor blocker and contrast induced nephropathy in patients receiving cardiac catheterization (CAPTAIN) trial. *Am Heart J* 170(1): 110-116.
54. ACT-Investigators (2011) Acetylcysteine for prevention of renal outcomes in patients undergoing coronary and peripheral vascular angiography: Main results from the randomized Acetylcysteine for Contrast-induced nephropathy Trial (ACT). *Circulation* 124(11): 1250-1259.
55. Li Y, Liu Y, Fu L, et al. (2012) Efficacy of short-term high-dose statin in preventing contrast-induced nephropathy: a meta-analysis of seven randomized controlled trials. *PLoS One* 7: e34450.
56. Sadat U, Usman A, Gillard JH, et al. (2013) Does ascorbic acid protect against contrast-induced acute kidney injury in patients undergoing coronary angiography: a systematic review with meta-analysis of randomized, controlled trials. *J Am Coll Cardiol* 62(23): 2167-2175.
57. DiMari J, Megyesi J, Udvarbelyi N, et al. (1997) N-acetylcysteine ameliorates ischemic renal failure. *Am J Physiol* 272(3): F292-F298.
58. Sun Z, Fu Q, Cao J, et al. (2013) Intravenous N-acetylcysteine for prevention of contrast-induced nephropathy: a meta-analysis of randomized, controlled trials. *PLoS One* 8(1): e55124.
59. Xu R, Tao A, Bai Y, et al. (2016) Effectiveness of n-acetylcysteine for the prevention of contrast-induced nephropathy: A systematic review and meta-analysis of randomized controlled trials. *J Am Heart Assoc* 5(9).
60. Leoncini M, Toso A, Maioli M, et al. (2014) Early high-dose rosuvastatin for contrast-induced nephropathy prevention in acute coronary syndrome: results from the PRATO-ACS Study (Protective Effect of Rosuvastatin and Antiplatelet Therapy On contrast-induced acute kidney injury and myocardial damage in patients with Acute Coronary Syndrome). *J Am Coll Cardiol* 63(1): 71-79.
61. Han Y, Zhu G, Han L, et al. (2014) Short-term rosuvastatin therapy for prevention of contrast-induced acute kidney injury in patients with diabetes and chronic kidney disease. *J Am Coll Cardiol* 63(1): 62-70.
62. Trivedi HS, Moore H, Nasr S, et al. (2003) A randomized prospective trial to assess the role of saline hydration on the development of contrast nephrotoxicity. *Nephron Clin Pract* 93(1): C29-C34.
63. Solomon R, Werner C, Mann D, et al. (1994) Effects of saline, mannitol, and furosemide to prevent acute decreases in renal function induced by radiocontrast agents. *N Engl J Med* 331: 1416-1420.
64. Solomon R, Gordon P, Manoukian SV, et al. (2015) Randomized trial of bicarbonate or saline study for the prevention of contrast-induced nephropathy in patients with CKD. *Clin J Am Soc Nephrol* 10(9): 1519-1524.
65. Brar SS, Shen AY, Jorgensen MB, et al. (2008) Sodium bicarbonate vs. sodium chloride for the prevention of contrast medium-induced nephropathy in patients undergoing coronary angiography: a randomized trial. *JAMA* 300(9): 1038-1046.
66. Brar SS, Aharonian V, Mansukhani P, et al. (2014) Haemodynamic-guided fluid administration for the prevention of contrast-induced acute kidney injury: the POSEIDON randomized controlled trial. *Lancet* 383: 1814-1823.
67. Weisbord SD, Palevsky PM (2010) Strategies for the prevention of contrast-induced acute kidney injury. *Curr Opin Nephrol Hypertens* 19(6): 539-549.
68. Briguori C, Visconti G, Focaccio A, et al. (2011) Renal insufficiency after contrast media administration trial ii (remedial ii): renalguard system in high-risk patients for contrast-induced acute kidney injury. *Circulation* 124(11): 1260-1269.
69. Marenzi G, Ferrari C, Marana I, et al. (2012) Prevention of contrast nephropathy with furosemide-induced diuresis and matched hydration—The MYTHOS trial. *JACC Cardiovasc Interv* 5(1): 90-97.

70. Solomon R (2014) Forced diuresis with the Renal- Guard system: impact on contrast induced acute kidney injury. *J Cardiol* 63(1): 9-13.
71. Briguori C, Visconti G, Donahue M, et al. (2016) Renal Guard system in high-risk patients for contrast-induced acute kidney injury. *Am Heart J* 173: 67-76.
72. Crimi G, Ferlini M, Gallo F, et al. (2014) Remote ischemic postconditioning as a strategy to reduce acute kidney injury during primary PCI_ a post-hoc analysis of a randomized trial. *Int J Cardiol* 177(2): 500-502.
73. Bei WJ, Duan CY, Chen JY, et al. (2016) Remote ischemic conditioning for preventing contrast-induced acute kidney injury in patients undergoing percutaneous coronary interventions/coronary angiography: a meta-analysis of randomized controlled trials. *J Cardiovasc Pharmacol Ther* 21(1): 53-63.
74. Andò G, Cortese B, Russo F, et al. (2017) Acute kidney injury after Radial or Femoral Access for Invasive Acute Coronary Syndrome Management: AKI-MATRIX. *J Am CollCardiol* S0735-1097(17): 36897-36903.

***Corresponding author:** Gabriele Crimi, MD, Division of Cardiology, Fondazione IRCCS Policlinico San Matteo, Piazzale Golgi 1, 27100 Pavia, Italy, Tel: +39 0382 50 1598, Fax: +39 0382 50 3171; E-mail: gabrielecrimi@gmail.com

Received date: August 27, 2017; **Accepted date:** September 28, 2017; **Published date:** October 02, 2017

Citation: Mandurino-Mirizzi A, Crimi G (2017) Contrast-induced Acute Kidney Injury: A Review. *Front Med Health Res* 1(1): 103.

Copyright: Mandurino-Mirizzi A, Crimi G (2017) Contrast-induced Acute Kidney Injury: A Review. *Front Med Health Res* 1(1): 103.